

Effect of Ultrasound Therapy on the Repair of Gastrocnemius Muscle Injury in Rats

Maria Cristina Piedade¹, Milena Sanches Galhardo², Cláudia Naves Battlehner¹,
Marcelo Alves Ferreira¹, Olga Maria Toledo², Elia Garcia Caldini¹

¹Laboratory of Cell Biology, The University of São Paulo School of Medicine, Av. Dr Arnaldo 455, São Paulo, Brazil, phone/fax: +55 11 3061-7241, Email: cris.piedade@uol.com.br

²Department of Morphology, The Federal University of São Paulo, São Paulo, Brazil

BACKGROUND: Considering that ultrasound (US) treatment stimulates both proliferation of myogenic cells and collagen deposition which, theoretically, could impair further cell proliferation, it was thought to be of interest to proceed to a quantitative study of collagen and myogenic cells in a rat muscle laceration injury model treated by pulsed US.

METHODS: Morphometric techniques in association with the Picosirius-polarization method (for collagen identification) and with immunodetection of desmin (a myogenic cells marker) were carried out in tissue sections. We compared untreated operated controls with animals treated daily with 1MHz pulsed US(50%) at 0.57 W/cm² for 5min (beginning 2 days post-trauma). Five treated and five control animals were sacrificed at 4, 7 or 14 days post-trauma.

RESULTS: The areal fraction (in percentage) occupied by collagen was higher in treated lesions in all post-injury time spans studied: 4 days (17.53±6.2 vs 6.79±1.3, p=0.0491), 7 days (31.07±7.4 vs 12.57±3.6, p=0.0021) and 14 days (41.66±2.97 vs 34.83±3.08, p=0.025). The areal fraction of myoblasts and myotubes was larger in the treated lesions at 14 days after surgery (41.66±2.97 vs 34.83±3.08, p=0.025). Figure 1-8 illustrate our results.

CONCLUSIONS: Our data suggest that although the pulsed US induced the deposition of collagenous fibers, there was a larger amount of myotubes at 14 days post-trauma in US treated lesions, suggesting that the increase on collagen deposition and aggregation promoted by the US was not enough to impair muscle cell growth and differentiation.

DISCLOSURES: Supported by LIM FMUSP and published in *Ultrasonics* 48, 403-11, 2008.

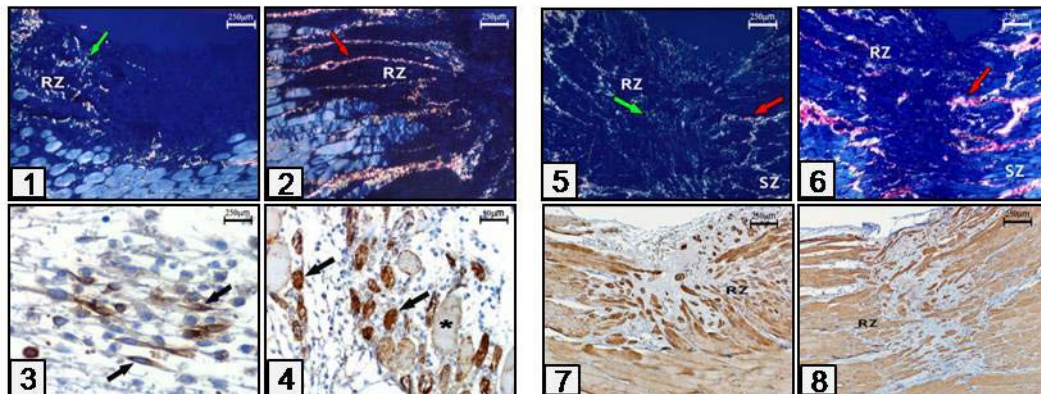


Fig. 1-4. Transverse sections of muscle lesion at 4 days post-trauma stained with Picosirius observed under polarized light (1,2) and immunostained for desmin (3,4). Control (1,3) and US treated (3,4) lesions. (1) Collagenous fibers show up as a mesh of very thin weakly birefringent structures (arrow). (2) In contrast, the US treated lesion shows a well developed Regeneration Zone (RZ) with plenty of strongly birefringent thicker collagen fibers (arrow). (3) Desmin-positive myoblasts (arrows). (4) Newly formed myotubes (arrows) among the surviving myofibers (*).

Fig. 5-8. Sections of muscle lesion at 14 days post-trauma stained with Picosirius observed under polarized light (5,6), and immunostained for desmin (7,8). Control (5,7) and US treated (6,8) lesions. (5) Most of fibrillar collagen appears as a framework of thin fibers. (6) Collagen appears as bundles of aligned strongly birefringent fibers (arrow) in sharp contrast with multidirectional arrangement of collagen in picture 5. (7) In untreated lesions the orientation of the regenerating muscle cells is disturbed and they are disposed in multiple directions. (8) In US treated lesions there is a more regular pattern of the myotubes and myofibers which are aligned roughly parallel to each other.